

Histopathological Effects of Single Dose Treatment of Diazinon on Testes Structure in Rat

Seyed Gholam Ali Jorsaraei, Ph.D.^{1*}, Alireza Firoozjaee, M.D.², Yousofreza Yousofnia Pasha, M.D.¹, Eisa Tahmasbpour Marzony, M.Sc.³, Ebrahim Sarabi, M.D.⁴

1. Fatemeh Zahra Infertility and Health Reproductive Research Center, Babol University of Medical sciences, Babol, Iran

2. Pathology Department, Babol University of Medical Science, Babol, Iran

3. Biology Department, Faculty of Basic Science, University of Mazandaran, Babolsar, Iran

4. Babol University of Medical Science, Babol, Iran

* Corresponding Address: P.O.Box: 4717641367, Fatemeh Zahra Infertility and Health Reproductive Research Center, Babol University of Medical sciences, Babol, Iran
Email: alijorsara@yahoo.com

Received: 11/May/2009, Accepted: 9/Jun/2009

Abstract

Objective: Diazinon (DZN) is an organophosphorate synthetic insecticide widely used in agriculture. DZN has been observed to cause many changes, such as alterations in androgenic hormones. In the present study, the effect of DZN treatment on the structure of the testes and spermatogenesis in young adult Albino rats was evaluated.

Materials and Methods: Adult rats were randomly divided into three groups including: controls (n=6), DZN-treatment group A (n=6) and DZN-treatment group B (n=6). Commercial DZN was injected intraperitoneally in a single dose (A=25 mg/kg and B=2.5mg/kg), corresponding to LD50. Thirty five days after injection, animals were sacrificed for morphological and histological examinations.

Results: There was a significant reduction in seminiferous tubule size in group A in comparison with both controls and group B ($p<0.001$). The number of spermatocytes, Leydig and germinal cells were significantly decreased ($p<0.001$). These differences were not significant between the controls and group B; however, the number of spermatocytes in group B was significantly lower than in the controls ($p<0.01$).

Conclusion: This study revealed that the reproductive function of adult rats and spermatogenesis are sensitive to DZN treatment. In addition, the effect of DZN on morphological parameters was significantly dose dependent. Further study of the control DZN and the actual mechanism whereby it exerts toxic effects on male infertility is required.

Keywords: Rats, Testes, Diazinon, Spermatogenesis

Yakhteh Medical Journal, Vol 12, No 1, Spring 2010, Pages: 39-42

Introduction

The use of pesticides in agriculture for crop protection and pest control has been associated with environmental contamination and human health problems worldwide (1, 2). Several studies have suggested that the quality of human semen has declined over past decades and some have associated this with occupational exposure to pesticides (3, 4). However, although published studies have reported an association between pesticide exposure and male reproduction (5-8), the actual adverse role of pesticides on male reproductive function has been a matter of debate. Hence, the effect of pesticides on human reproduction remains controversial and in many studies growing interest has been focused on the wide family of pesticides (4).

Nowadays, contact with organophosphorus pesticides (OP) is an important health problem for agri-

cultural workers (1). Although rapidly metabolized, they are highly toxic for insects and mammals. DZN is an organophosphorate pesticide (OP) widely used in agricultural practice throughout the world to control flies, lice, and insect pests of ornamental plants and food crops (9). There have been increasing concerns about the effects of DZN in human and experimental animals. It inhibits acetylcholinesterase activity and other organic functions (10, 11). Some researchers have shown that DZN leads to alterations in blood factors, plasma testosterone and glucose levels in male rats (12, 13). Nevertheless, the toxic effect of DZN on male reproductive function is not well known. Some studies have indicated that DZN has the capacity to disrupt reproductive function in animals (14-17). Conversely, others studies have reported the pathological effects of DZN on human reproductive function with decreased libido

after percutaneous treatment and significantly decreased androgenic hormone level (18).

Since the negative effect of DZN on male reproductive function remains controversial, in the present study we hypothesized that DZN has a detrimental effect on rat testes structure and can be a risk factor for deficient spermatogenesis. The number of spermatocytes, Leydig and germinal cells, and seminiferous tubule size were analyzed for an appraisal of spermatogenesis.

Materials and Methods

Animals and materials

Eighteen Albino male rats, 70-80 days of age, were obtained from the Pastor Institute (Experimental Animal Center, Tehran, Iran). The rats were housed singly in a room with an ambient temperature of 20°C and a 12:12 light/dark cycle. Diazinon [O,O-diethyl O (2-isopropyl-6-methyl-4-pyridinyl) phosphorothioate, 60% pure, boiling point 83-84°C, denaturation point 120°C and specific gravity of 1/116-1/118] was provided from international agricultural chemistry.

Treatment with DZN

On the morning of day 1, adult rats were randomly divided into two groups including: controls (n=6) and DZN-treatment groups (n=12). The DZN-treatment groups were divided into two subgroups A (n=6) and B (n=6), according to dosage levels. On the afternoon of day 1, the animals were intraperitoneally (ip) injected with a single dose of DZN (25 mg/kg for group A and 2.5 mg/kg for group B). The controls received the same volume of deionized water. All animal-related protocols were approved by the Institutional Animal Care and Use Committee (Babol University of Medical Sciences-Iran).

Tissue processing and morphological observation

On day 35, animals were sacrificed for morphological and histological examinations. Testes were removed and fixed in 10% formalin for at least 48h. Tissue fragments were dehydrated in graded series of ethanol, embedded in paraffin and sectioned using an automatic microtome (Designed

by ERNST Leitz WELZLAR, model feitz 1512) at 5 mm thickness. For histological processing, the sectioned tissues were stained with hematoxylin-eosin and examined for morphological and histological parameters (including: germinal cell, Leydig cell and spermatocyte (primary & secondary) counts and seminiferous tubule diameters) by light microscopy. The numbers of germ cells, spermatocytes and Leydig cells were measured using a stage micrometer calibrated with an eyepiece micrometer. The seminiferous tubule diameters (STD) were measured using an eyepiece graticule that consisting conversions table bound to microscope. For each sample, 400 tubules measured.

Statistical analysis

Data are reported as means \pm SD. An independent t test was used to compare means between the 2 groups (DZN treated group vs control group). A probability of less than 0.05 was considered as significant. Data were analyzed using SPSS, version 11.5 (SPSS Inc, Chicago, Ill) (FAQ).

Results

Group A showed a significant decrease in the numbers of germinal ($p<0.001$), Lydig ($p<0.001$) and spermatocyte (primary & secondary) cells ($p<0.01$) when compared to the controls. These differences were not significant between controls and group B, however, the numbers of spermatocytes in group B were significantly lower than in the control group (Table 1; $p<0.01$). The numbers of germinal cells, Lydig cells and spermatocytes in group A were significantly lower than those in group B [(7.34 vs. 9.84; $p<0.001$); (8.52 vs. 10.97; $p<0.001$); (41.39 vs. 46.11; $p<0.01$)].

The diameters of seminiferous tubules were smaller in groups A and B, but a significant difference was seen only in group A compared to the control group ($p<0.01$, Table 1). The structures of the seminiferous tubules in DZN-treatment groups were pathologically damaged (Fig 1B, C) in comparison to the control group (Fig 1A).

Table 1: Comparison of histological parameters in all groups after exposure to DZN

| Parameters | Control | Group A | Group B |
|---|------------------|-------------------|--------------------|
| Germinal cell count | 9.84 \pm 0.64 | 7.34 \pm 0.87* | 9.56 \pm 0.86 |
| Lydig cell count | 10.97 \pm 1.2 | 8.52 \pm 0.82* | 10.31 \pm 0.92 |
| Primary and secondary Spermatocytes count | 46.11 \pm 2.58 | 41.39 \pm 2.9* | 44.78 \pm 2.74** |
| Seminiferous tubule diameters (μ m) | 4.85 \pm 0.36 | 3.98 \pm 0.47** | 4.56 \pm 0.33 |

Results are presented as Mean \pm SD * $p<0.001$; ** $p<0.01$, *** $p<0.001$

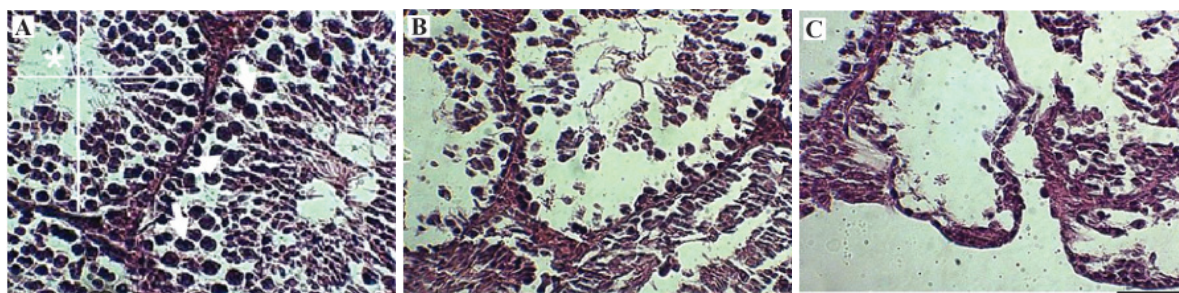


Fig 1: Testicular structure of the (A) control Rats ($\times 100$), (B) DZN-treated group B (2.5 mg/kg) ($\times 100$) and (C) DZN-treated group A (25 mg/kg) ($\times 100$). The pathologic effects of DZN on group A were significantly higher when compared to both controls (A) and group B (B). The structures of the seminiferous tubules in group A were severely damaged (C) and the thickness of the tubular walls was reduced. Slight differences were found in group B. The number of germinal cells was greatly decreased in group A. Arrows indicate the location of germinal cells. Asterisk shows the seminiferous tubule size.

Discussion

Reproductive abnormalities caused by organophosphate (OP) have been observed in many vertebrates, such as inhibition of spermatogenesis in fish and mice (15, 19, 20). Alteration of germinal cell DNA, seminiferous epithelium and low quality of sperm have been reported previously (4, 8, 14, 19, 21-26). Alahyary et al. (12) have shown that blood glucose and testosterone levels were increased in a DZN treated group compared with a control group, moreover the number of red blood cells (RBC) in the DZN group was significantly decreased in comparison with the controls. Dikshith et al (27) observed mild structural and functional changes in rat testes after a single ip administration of DZN. Dutta and Meijer (15) investigated the toxic effects of DZN on the structure of the testis of bluegill fish. They found a significant change in the germ cells and seminiferous tubule diameters (15). In the present study we found that DZN had a significant effect on the structure of rat testes. There was a significant reduction in both seminiferous tubule size and germinal cell count in the DZN-treatment groups, especially group A. As germ cells are the essential first step in the process of spermatogenesis, a reduction in their count may hinder the production of viable spermatozoa (15). Contreras et al. (28) have shown that the number of Leydig cells and steroidogenesis are acutely and deeply damaged by OP injection in mice. In our study the number of Leydig cells was significantly decreased by DZN-treatment. Testicular Leydig cells are the main site of testosterone synthesis (28). This steroidal hormone plays a key role in the maintenance of spermatogenesis, male sex characteristics and fertility (28). As a consequence of impaired Leydig cell activity, male infertility may result (28). Some studies have shown that a decreased testicular Leydig cell count is associated with decreased testosterone production, which may result in spermatogenic deficiencies (15, 18). According to this research and the present study, DZN has toxic effects on male reproduction. In our study

the toxic effect of DZN on rat testes in group A was significantly higher than that in group B. These data suggest that the toxic effects of DZN on rat testes are dose dependent. Although this reproductive dysfunction is typically characterized by disruptions in spermatogenesis and loss of fertility, the actual mechanisms involved in DZN-induced infertility remain unclear. Kurodak et al. (29) explained that DZN led to cell injury by mitotic toxicity, chromatin destruction and DNA disturbances. Some research has shown decreased testosterone production by Leydig cells in DZN treated groups to be one of these mechanisms (18, 28, 30). The Leydig cells produce the testosterone needed in the seminiferous tubules to induce the differentiation of spermatogonia to spermatozoa (28). Because testicular Leydig cells play a critical role in male reproductive function, alterations in the Leydig cells could be due to many different pathological or experimental situations associated with spermatogenesis deficiency (31, 32).

Reactive oxygen species (ROS) caused by OP may be involved in the toxicity of various pesticides (32). Increased ROS may decrease the effective concentration of antioxidant, increasing the harmful effects of ROS to reproductive tissue (3). Sutcu et al. (33) have shown that DZN treatment caused an increase in lipid peroxidation (LPO) in rat erythrocytes. Because spermatozoa have large quantities of polyunsaturated fatty acids (PUFA) in their plasma membranes and their cytoplasm contains low concentrations of scavenging antioxidants (3), a causal relationship is suspected. Thus, it is hypothesized that oxidative damage induced by DZN may be one of these mechanisms which merit future study.

Conclusion

Our results suggested an adverse effect of DZN on histomorphological parameters and spermatogenesis of rat testes. The toxic effect of DZN on rat testes is dose dependent. Although further research is needed to clarify and improve this result in relation

to human reproduction, couples attempting pregnancy should be individually counseled regarding any potentially harmful occupational exposures.

Acknowledgments

The authors thank Dr. Ali Akbar Moghaddamnia, Dr. Reza Alizadeh, and Mr Faraji, Mr Jafari and Mr Musavi for their help. There is no conflict of interest in this study.

References

1. Hurtig AK, San Sebastian M, Soto A, Shingre A, Zambrano D, Guerrero W. Pesticide use among farmers in the Amazon basin of Ecuador. *Arch Environ Health*. 2003; 58: 223-228.
2. Soares W, Almeida RMR, Moro S. Rural work and risk factors associated with pesticide use in Minas Gerais. *Brazil Cad Saude Publica*. 2003; 19: 1117-1127.
3. Agarwal A, Prabakaran SA. Mechanism, measurement and prevention of oxidative stress in male reproductive physiology. *Indian J Experim Biol*. 2005; 43: 963-974.
4. Recio-Vega R, Ocampo-Gomez G, Borja-Aburto VH, Moran-Martinez J, Cebrian-Garcia ME. Organophosphorus pesticide exposure decreases sperm quality: association between sperm parameters and urinary pesticide levels. *J Appl Toxicol*. 2008; 28: 674-680.
5. Bustos-Obregon E, Gonzalez-Hormazabal P. Mice testicular damage elicited by Malathion. *Int J Morphol*. 2003; 21: 155-159.
6. Dutta HM, Dalal R. The effect of endosulfan on the ovary of bluegill sunfish: A histopathological study (*Lepomis macrochirus*). *Int J Environ Res*. 2008; 2: 215-224.
7. Dutta HM, Maxwell LB. Histological examination of sublethal effects of diazinon on ovary of bluegill, *Lepomis macrochirus*. *Environ Pollut*. 2003; 121: 95-102.
8. Oliveira-Silva JJ, Alves SR, Meyer A, Perez F, Sarcinelli PN, Da Costa Mattos RC, et al. Influence of socio-economic factors on the pesticides poisoning, Brazil. *Rev Saude Publica*. 2001; 35: 130-135.
9. Paroanu LE, Mocko JB, Becker-Roek M, Smidek-Huhn J, Layer PG. Exposure to diazinon alters in vitro retinogenesis: retinospheroid morphology, development of chicken retinal cell types, and gene expression. *Toxicol Scien*. 2006; 89: 314-324.
10. Ceron JJ, Ferrando MD, Sancho E, Gutierrez-Panizo C, Andreu-Moliner E. Effects of diazinon exposure on cholinesterase activity in different tissues of European eel (*Anguilla anguilla*). *Ecotoxicol Environ Saf*. 1996; 35(3): 222-225.
11. Ozcan-Oruc E, Uner N, Sevgiler Y, Usta D, Durmaz H. Sublethal effects of organophosphate diazinon on the brain of *Cyprinus carpio*. *Drug Chem Toxicol*. 2006; 29: 57-67.
12. Alahyary P, Ilkhani poor M, Fathy Azarbaijani F, Nejati V. The potential toxicity of diazinon on physiological factors in male rat. *Pak J Biol Sci*. 2008; 11: 127-130.
13. Ueyamaa J, Kamijimac M, Asai K, Mochizuki A, Wangc D, Kondob T, et al. Effect of the organophosphorus pesticide diazinon on glucose tolerance in type 2 diabetic rats. *Toxicolo Lett*. 2008; 182: 42-47.
14. Bustos Obregon E, Gonzalez JR, Espinoza O. Melatonin as protective agent for the cytotoxic effects of diazinon in the spermatogenesis in the earthworm *Eisenia foetida*. *Ital J Anat Embryol*. 2005; 110: 159-165.
15. Dutta HM, Meijer HJ. Sublethal effects of diazinon

- on the structure of the testis of bluegill, *Lepomis macrochirus*: a microscopic analysis. *Environ Pollut*. 2003; 12: 355-360.
16. Rodriguez H, Bustos-Obregon E. An in vitro model to evaluate the effect of an organophosphoric agropesticide on cell proliferation in mouse seminiferous tubules. *J Androl*. 2000; 32: 1-5.
17. Yehia MA, El-Banna SG, Okab AB. Diazinon toxicity affects histophysiological and biochemical parameters in rabbits. *Exp Toxicol Pathol*. 2007; 59: 215-225.
18. Maxwell LB, Dutta HM. Diazinon-induced endocrine disruption in bluegill sunfish, *Lepomis macrochirus*. *Ecotoxicol Environ Saf*. 2005; 60: 21-27.
19. Contreras H, Bustos-Obregon E. Morphological alterations in mouse testes by a single dose of Malathion. *J Exp Zool*. 1999; 284: 355-359.
20. Sobarzo C, Bustos-Obregon E. Sperm quality in mice acutely treated with parathion. *Asian J Androl*. 2000; 2: 147-150.
21. Contreras H, Badilla J, Bustos-Obregon E. Morphofunctional disturbances of human sperm after incubation with organophosphate pesticides. *Biocell* 1993; 23: 135-141.
22. Del Valle LJ, Bustos-Obregon E, Contreras HR. Male reproductive toxicology of organophosphate agropesticide. *Current Topics Toxicol*. 2004; 1: 125-133.
23. Espinoza-Navarro O, Bustos-Obregon E. Effect of Malathion on the male reproductive organs of earthworms, *Eisenia foetida*. *Asian J Androl*. 2005; 7: 97-101.
24. Pina Guzman B, Solis Heredia MJ, Quintanilla Vega B. Diazinon alters sperm chromatin structure in mice by phosphorylating nuclear protamines. *Toxicol Appl Pharma*. 2005; 202: 189-198.
25. Rojas M, Bustos-Obregon E, Martinez-Garcia F, Contreras H, Regadera J. The effect of parathion on mouse testicular and epididymal development cultured in chicken allantochorion. *Adv Exp Med Biol*. 1998; 444: 201-206.
26. Swan SH. Semen quality in fertile US men in Relation to geographical area and pesticide exposure. *Int J Androl*. 2006; 29: 62-88.
27. Dikshith TS, Behari JR, Datta KK, Mathur AK. Effect of diazinon in male rats. *Histological and Biochemical studies*. *Environ Physiol Biochem*. 1975; 5: 239-299.
28. Contreras HR, Paredes V, Urquieta B, Del Valle L, Bustos-Obregon E. Testosterone production and spermatogenic damage induced by organophosphate pesticides. *Biocell*. 2006; 30: 423-429.
29. Kurodak yamaguchy, Endo G. Mitotic toxicity sister chromatid exchange, andrec assay of pesticides. *Arch Environ Contam Toxicol Japan*. 1992; 23: 13-18.
30. Abdel-Aziz MI, Sahlab AM, Abdel-Khalik M. Influence of diazinon and deltamethrin on reproductive organs and fertility of male rats. *Dtsch Tierarztl Wochenschr*. 1994; 101(6): 230-232.
31. Dufau ML, Cigorruga S, Baukal AJ, Bator JM, Neubauer JF, Catt KJ. Androgen biosynthesis in Leydig cells after testicular desensitization by LHRH and hCG. *Endocrin*. 1979; 105: 1314-1321.
32. Walsh LP, McCormick C, Martin C, Stocco DM. Roundup inhibits steroidogenesis by disrupting steroidogenic acute regulatory (StAR) protein expression. *Envi Health Perspec*. 2000; 108: 769-776.
33. Sutcu R, Altuntas I, Buyukvanli B, Akturk O, Ozturk O, Koylu H, et al. The effects of diazinon on lipid peroxidation and antioxidant enzymes in rat erythrocytes: role of vitamins E and C. *Toxicol Indust Health*. 2007; 23: 13-17.