

# Effect of Intrathecal Transplantation of Adrenal Medullary Tissue on the Sciatic Nerve Regeneration Following Chronic Constriction Injury in the Rat

Homa Manaheji, Ph.D.<sup>☆</sup>, Farinaz Nasirinezhad Ph.D.<sup>☆‡</sup>, Gila Behzadi, Ph.D.<sup>☆</sup>

<sup>☆</sup> Physiology Department and Neuroscience Center, Shaheed Beheshti University of Medical Sciences

<sup>☆</sup> Physiology Department, Iran University of Medical Sciences

<sup>‡</sup> Corresponding Address: P.O. Box: 19835-181, Physiology Department and Neuroscience Center, Shaheed Beheshti University of Medical Sciences, Tehran, Iran

Email: hmanaheji@yahoo.com

## Abstract

Received: 24/Apr/2005, Accepted: 21/Aug/2005

**Introduction:** It has been demonstrated that the adrenal medullary transplants into the spinal subarachnoid space can alleviate neuropathic pain behaviors. The aim of the present study was to test the possibility that histological changes of the sciatic nerve in a neuropathic model as well as sensory dysfunction are repaired by adrenal medullary transplantation.

**Material and Methods:** Left sciatic nerve was ligated in three groups of rats by 4 loose ligatures (CCI). After one week of nerve constriction, rats of first group were implanted with adrenal medullary tissue (CCI + adrenal medulla) and rats of the second group with striated muscle at the level of L1-L2 (CCI + muscle). The third group received only left ligature (CCI) and in the fourth group the sciatic nerve was exposed and then muscle and skin sutured (sham).

Behavioral assessment was evaluated before surgery and 2, 4, 7, 10, 14, 21, 28, 42, and 56 days after the onset of experiment. According to behavioral results, 4 rats in each group were anesthetized and then the distal part of sciatic nerve were isolated and prepared for histological quantitative investigation of nerve regeneration.

**Results:** The results showed that CCI was accompanied with hyperalgesia and morphological changes in the distal part of sciatic nerve. In animals with adrenal medullary transplantation, not only hyperalgesia was markedly reduced or even eliminated, but also the number of myelinated fibers in the distal segment of nerve increased to nearly normal.

**Conclusions:** Our findings showed that the implantation of adrenal medullary tissue might have caused regeneration of ligated nerves as well as alleviation of pain behavior.

**Keywords:** neuropathy, transplantation, sciatic nerve, adrenal medullary, semi-thin section

*Yakhteh Medical Journal, Vol 7, No 2, Summer 2005, Pages: 68-73*

## Introduction

A mononeuropathy induced in rat by 4 loose ligatures around the common sciatic nerve (CCI) has been recently proposed as a model of experimental pain. There is now growing evidence that chronic constriction injury model produces behaviors in the rat such as hyperalgesia, thermal and mechanical allodynia, and spontaneous pain

that in some aspects are reminiscent of reports from patients with painful neuropathy (1, 2). So this model has proved useful for testing the anti-allodynic or anti-hyperalgesic effect of various therapeutic interventions (3). Lindenlaub (2000) and Gillespie (2000) have shown the microscopic evidence for the relationship between maximal hyperalgesia and

histological changes in the distal part of sciatic nerve in CCI model (4, 5). Two weeks after nerve constriction, at the peak of pain, large myelinated fibers were massively degenerated. Moreover, a large proportion of the small myelinated fibers were also interrupted at the site of injury and the remaining fibers distal to the ligation showed pathological properties (6). As a general rule, peripheral neuropathies involve large as well as small fiber dysfunction (7).

The feasibility of cell or tissue transplantation into the CNS has long been of theoretical interest, but has only become of practical interest in more recent years. Tissues implanted into appropriate regions of the CNS can act as pharmacological minipumps providing a continually renewable supply of neuroactive agents (8). In this regard, a lot of studies have been focused on the role of chromaffin cells in pain alleviation and reconstruction of neural network. Yu (1998) and Siegan (1998) demonstrated chromaffin cells of adrenal medulla produced and released several neuroactive substances including catecholamines, enkephalins, and growth factors, which could have analgesic effects (9, 10). In addition, there are some evidence based on the role of growth factors in prevention of axonal degeneration and promotion of fiber regeneration following axonal injury (11).

Because of close relationship between histological changes and induced hyperalgesia, in this study we have attempted to clarify if intrathecal transplantation of adrenal medullary tissue has any regenerative effects on the CCI model of sciatic nerve in rat following observed behavioral analgesia. For this purpose, we used light microscopic semi-thin section technique. A preliminary result of this work was presented in 10th world congress on pain, 2002.

## Material and Methods

This study was conducted according to the guidelines of the Ethical Committee of the International Association for the Study of Pain (IASP). Male Sprague-Dawley rats weighing 250-300 g were used as both graft donors and recipients. Animals were housed in separate cages and had free access to water and standard rat chow during experiments. The animals were divided into

four groups (n=8 in each group). Prior to peripheral nerve ligation, the pain behavior of the rats were assessed to establish the baseline responses, as well as 2, 4, 7, 10, 14, 21, 28, 42, and 56 days following peripheral nerve ligation [left ligation (CCI), sham (only nerve exposed)] and transplantation [(CCI + adrenal medulla), (CCI + muscle)]. These time points were chosen based on the previous reports with the CCI model. For histological study, 4 rats in each group were used.

### *Surgical procedures*

For surgical procedure, the rats were anaesthetized with a mixture of Ketamine and Rampon (60 mg/kg). Four loosely ligations (by 4/0 chromic gut) were tied around the sciatic nerve according to Bennet and Xie model to induce the neuropathic pain (1). In sham operated group, the sciatic nerve was exposed, but not ligated. To minimize the differences in the technique used, the same person performed the operation in all groups.

One week after nerve surgery, animals in transplanted groups were anaesthetized and implanted with either adrenal medullary tissue or striated muscle tissue. Before transplantation, the tissues were cut under dissecting microscope into small pieces (0.5 mm<sup>3</sup>) in cold nutritional buffer. The tissue obtained from two adrenal glands was implanted to each recipient.

Equal volumes of striated muscle tissue from thoracolumbar fascia in the posterior side of donor animals were implanted as graft controls. At the time of transplantation, laminectomy was performed to expose the lumbar enlargement and the tissues were implanted in subarachnoid space. Following implantation, the musculature and skin were closed in layers.

### *Sensory assessment*

Mechanical hyperalgesia was determined by paw pinch test. So a standard pinch of the hindpaw midplantar skin was set up by a forceps with smooth active surfaces which made a consistent pinching force. The animal's response was scored as follows: 0= no response, 1= 2-3 second withdrawal latency, 2= immediate hindpaw withdrawal, 3= immediate withdrawal of hindpaw and leg, 4= immediate withdrawal of hindpaw and leg plus vocalization (12).

**Morphological and statistical analysis**

According to behavioral test, rat sciatic nerves (n=16, 4 in each group) in ligated paws were prepared for histological analysis 2 and 8 weeks after CCI and one week after transplantation. In this regard the rats were deeply anesthetized with a mixture of Ketamine-Rampon (100 mg/kg) and the distal 0.5 cm of each sciatic nerve was dissected. The excised piece of nerves was immediately immersed in 4% glutaraldehyde in 0.1 M phosphate buffer (pH 7.4) for 24 hours at 4°C.

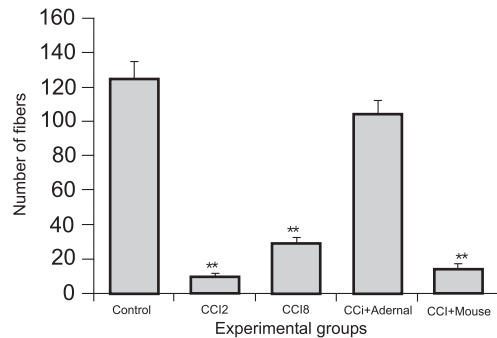
Tissues were then post-fixed in 1% osmium tetroxide for 3 hours, dehydrated in serial alcohol concentrations, and embedded in Epon. Ultramicrotome semi-thin cross sections (0.5 µm thick) were mounted on glass slides and stained with toluidine blue for light microscopic evaluation. For qualitative and quantitative evaluation, 2 photomicrographs from two different parts of the tibial nerve (the largest fascicle in sciatic nerve) were taken from each animal. In total, 8 photomicrographs from each group were used. Myelinated fibers were counted by using a transparent paper, which was marked out every 2 cm (2).

Data were analyzed using ANOVA and the Newman-Keuls test for comparisons. All results were reported as mean ± SEM. The results were declared significant if p<0.05, p<0.001.

**Results**

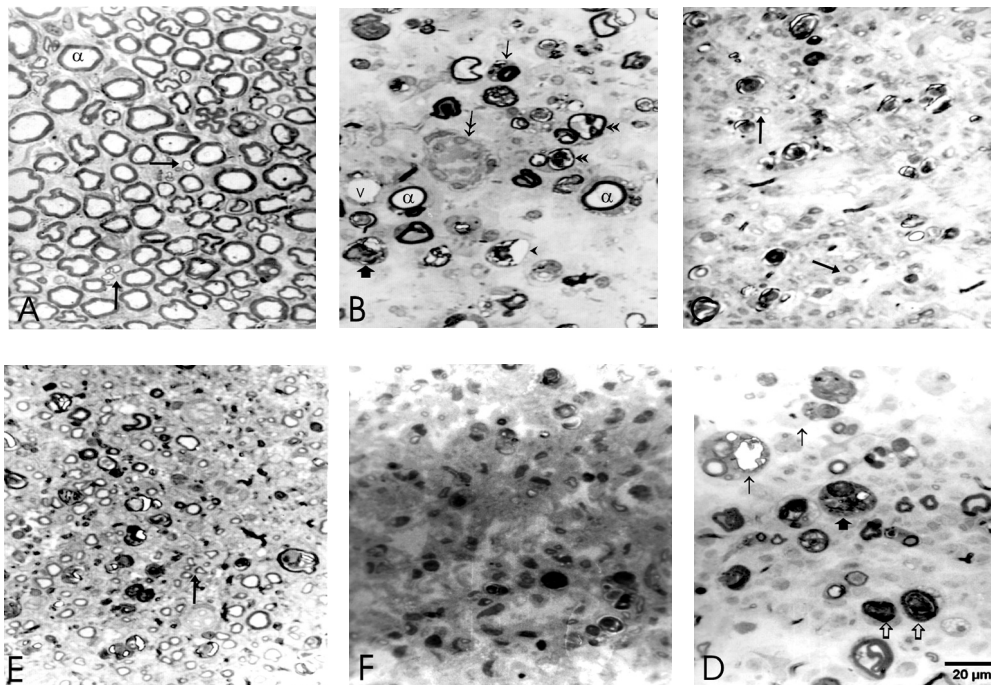
**Behavior**

The score of the hindpaw withdrawal reflex in response to mechanical stimuli is shown in Fig. 1.



**Figure 1.** Withdrawal threshold to pressure at the same side of sciatic loose ligature in experimental groups. CCI= left ligation, Sham=sciatic nerve exposed and then muscle and skin sutured, CCI + adrenal medulla= left ligation + adrenal medulla transplantation, CCI + muscle= left ligation + muscle transplantation. All groups were compared with the control day (day zero).

\*Indicates a significant difference (p<0.05), \*\*Indicates a significant difference (p<0.01).



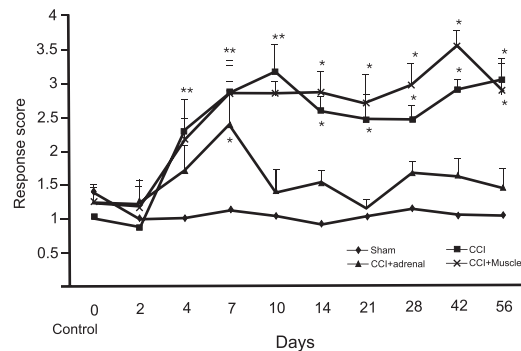
**Figure 2.** Photomicrographs of toluidine blue stained semi-thin cross sections from normal sciatic (control or A). CCI2 or B = two weeks after CCI. CCI8 or C = eight weeks after CCI. D = one week after adrenal medullary transplantation with considerable reduction in myelinated fibers. CCI + adrenal or E = seven weeks after adrenal medullary transplantation compared to its equal muscle transplanted control is obvious. Small myelinated fibers (arrows) are shown in A, C & E, ruffled basal lamina (double head arrow) in B, Schwann cells or phagocytotic cells containing myelin debris (thin arrows) in B & D, damaged axons (thick arrows) in B & D. Phagocytotic lysosomes (small arrows) in D, atrophic axons (double arrow heads) and Schwann cells (arrow head) and blood vessel (V) in B.

Different scores were obtained in sham rats, nerve injured (CCI), and transplanted animals (CCI + adrenal medulla and CCI + muscle). In sham animals, the scores were not significantly different when compared with control day (day zero), but following CCI, significantly different scores on days 4, 7, 10 ( $p < 0.001$ ) and days 21, 28, 42, 56 ( $p < 0.05$ ) indicated mechanical hyperalgesia. The mechanical hyperalgesia reversed in animals with adrenal medullary implants. There were no significantly different scores in CCI + adrenal medullary group on days 10, 14, 21, 28, 42, and 56 when compared with control day (day zero), but there were significantly different scores in CCI + muscle group in most experimental days when compared with control day.

### Histology

All three branches including tibial, peroneal, and sural nerves were seen in cross section of sciatic nerve. There were no abnormalities in light microscopic examination of fascicle in sham operated rats compared to normal rats. Two weeks after chronic constriction injury, the presence of small capillaries showed that the ligation had not closed the vessels and the nerve changes were not related to lack of blood flow. Numerous fibroblasts with long processes could also be seen within the injured nerve (Fig. 2B). Phagocytic cells could be macrophages or Schwann cells, which contain a lot of myelin debris (Fig. 2B, D). The presence of Schwann cells with ruffled basal lamina suggested that the cytoplasm had atrophied or that the thin axons enclosed by Schwann cells were shrunken or absent (Fig. 2B). Damaged axons with degenerated myelins were distributed more or less homogeneously throughout the fascicle with no obvious consistent regional pattern. Interaxonal space was greatly increased and the order and packing density of the surviving myelinated axons was substantially diminished (Fig 2B, C). Two weeks after ligation, the number of myelinated fibers decreased considerably (Fig. 3) and few intact large diameter axons (A fibers) were visible in distal sections (Fig 2B). Eight weeks after injury, the number of myelinated fibers was still considerably less than control group (Fig. 3). Eight weeks after CCI, a few small myelinated fibers were also present (Fig. 2C). One week after transplantation,

the appearance of few fibers and numerous macrophages with phagocytotic lysosomes and large interaxonal space were still visible, as in untransplanted animals two weeks after CCI (Fig. 2D). Seven weeks after adrenal medullary transplantation, there was a significant increase in the number of small myelinated fibers with a thin myelin sheath compared to those in similar untransplanted or muscle transplanted animals (Fig. 3). The interaxonal space was also reduced considerably (Fig. 2E). Increase in the number of small myelinated fibers to near normal values might be due to early stages of regeneration and remyelination (Fig. 3). Seven weeks after muscle transplantation, there was no considerable change in the number of fibers and the nerves were apparently similar to those in untransplanted animals (Fig. 2F).



**Figure 3.** Total number of myelinated fibers in experimental group, compared to normal rats. CCI2= two weeks after CCI. CCI8= eight weeks after CCI. CCI + adrenal medulla = animals who received adrenal medullary transplantation. CCI + muscle = animals who received muscle transplantation. \*\* indicates the significant difference ( $p < 0.001$ ).

### Discussion

The present study demonstrated significant reduction in the proportion of myelinated fibers, particularly large ones, in distal part of fascicle two and eight weeks after CCI. It is note worthy that these histological changes in sciatic nerve were simultaneous with decrease in withdrawal latency to mechanical pressure as reported by others (3, 7). In our experiment, all fascicles lost nearly all of their large myelinated fibers as well as most of the small ones. However Basbaum *et al.* (1991) reported different characteristics in axonal damage in their experimental animals (13). Although Nuytten *et al.* (1992) reported regeneration of small myelinated fibers 2 weeks after ligation (6), but in the present investigation no fiber regeneration was seen in the second week (Fig. 2B). However, a few

regenerated fibers were observed eight weeks after ligation (Fig. 2C). Transplantation of adrenal medullary tissue considerably increased the number of myelinated fibers in distal part of the sciatic nerve seven weeks after transplantation (Fig. 2E). The differences between our results and theirs may be due to looser constriction of the nerve and technical variation. Adrenal chromaffin cells are currently used for lumbar transplantation in rat and human models for chronic pain. Several animal models have demonstrated that these transplants can alleviate both acute and chronic pain behaviors (14, 15). Chromaffin cell transplantation in a model of neuropathic pain and partial nerve injury was capable to reverse the behavioral hypersensitivity induced by the injury. Chromaffin cells capable of delivering neuroactive molecules offer a novel approach to cell therapy (16). Adrenal medullae were initially selected as donor tissues as they secrete several neuroactive substances including catecholamines, opioids, fibroblast growth factor, TGF- $\beta$ , interleukin-1, neurotrophin 4/5, NGF, and BDNF (17, 18). So it is difficult to assign the anti-nociceptive effects of a single agent produced by the cells. It is also likely that adrenal medullary implants reduce chronic pain by an alternate mechanism, since neither phentolamine nor naloxone reversed the beneficial effects of the implants on abnormal pain behavior (10).

It is note worthy that in various models of nerve injury producing chronic pain, the levels of neurotrophins such as BDNF and its mRNA is altered in DRG and dorsal horn (19). It was recently shown that exogenous BDNF had a direct positive effect on regeneration of the injured and intact neurons (20). In animals which the neural stem cells were transplanted to, the regeneration of axons improved by addition of neurotrophic factors (21). Indeed, the provision of repair factors by adrenal medullary grafts has been suggested as a possible mechanism for the observed functional improvements in Parkinson's disease models. In the presence of neurotrophins, budding of injured

dopaminergic fibers is possible (15). In addition, the hyperalgesia of peripheral nerve injury can be terminated by fiber regeneration (4).

Moreover, there are considerable evidence that some neurotrophins such as FGFs, BDNF, and GDNF are also important for survival of DRG neurons under normal circumstances and after nerve injury and are also required for peripheral nerve regeneration and remyelination (22, 23). It has been reported that neurotrophins such as BDNF and NT03 have functions such as an autocrine–paracrine survival factor in the regulation of central dendritic and axonal morphology (24, 25). So, production of trophic factors by neural transplants may be useful in the protection and restoration of injured neurons.

The discovery of retrograde transportation of neurotrophins by peripheral nerves opened a new window on the role of these molecules in neuronal development, degenerative neurological diseases, and neuronal regeneration. Thus survival and function of neurons depends on retrograde transportation of neurotrophic factors (23). Based on this evidence, it is likely that neuroactive substances such as neurotrophins released by adrenal medullary cells are retrogradely transported to DRG by nerve terminals, which in turn may result in budding and regeneration of nerve fibers. In this regard, the role of macrophages should be notified (26). We found that the cleaning action of phagocytic cells on their environment prepared it for fiber regeneration (Fig. 2B, D).

## Conclusion

The results of this study indicate that the adrenal medullary transplantation may regenerate the peripheral nerve subsequent to injury via its neuroactive substances and this might have caused alleviation of pain behaviors.

## Acknowledgement

This project was supported by The Research Deputy of Shahid Beheshti University of Medical Sciences and Neuroscience Research Center.

## References

1. Bennett GJ and Xie YK: A peripheral mononeuropathy in rat that produces disorders of pain sensation like those seen in man. *Pain* 1988; 33:87-107



2. Guilbaud G, Gautron M, Jazat F, Ratinahirana H, Hassig R, and Hauw JJ: Time course of degeneration and regeneration of myelinated nerve fibers following chronic loose ligatures of the rat sciatic nerve: can nerve lesions be linked to the abnormal pain related behaviours? *Pain* 1993; 53: 147-158
3. Roytta M, Wei H and Pertovaara A: Spinal nerve ligation-induced neuropathy in the rat: sensory disorders and correlation between histology of the peripheral nerves. *Pain* 1999; 80: 161-170
4. Lindenlaub T and Sommer C: Partial sciatic nerve transection as a model of neuropathic pain: a qualitative and quantitative neuropathological study. *Pain* 2000; 89: 97-106
5. Gillespie CS, Sherman DL, Fleetwood –Walker SM, Cottrell DF, Tait S, Garry EM, Wallace VC, Ure J, Griffiths IR, Smith A, Brophy PJ: Peripheral demyelination and neuropathic pain behavior in peri axon-deficient mice. *Neuron* 2000; 26: 523-31
6. Nuytten D, Kupers R, Lammens M, Dom R, Van Hees J and Gybels J: Further evidence for myelinated as well as unmyelinated fiber damage in a rat model of neuropathic pain. *Exp Brain Res* 1992; 91:73-78
7. Al-Shekhlee A, Chelimsky TC, Preston DC: Small-fiber neuropathy. *Neurol* 2002; 8: 237-53
8. Czech KA and Sagen J: Update on cellular transplantation into the CNS as a novel therapy for chronic pain. *Prog in Neurobiology* 1995; 46: 507-529
9. Yu W, Hao JX, Xu XJ, Saydoff J, Haegerstrand A, Hokfelt T, Hallin ZW: Long- term alleviation of allodynia-like behaviors by intrathecal implantation of bovine chromaffin cells in rats with spinal cord injury. *Pain* 1998; 115:122
10. Siegan JB, Sagen J: Adrenal medullary transplants attenuate sensorimotor dysfunction in rats with peripheral neuropathy. *Pharm Biochem Behav* 1998; 59: 97-104
11. Saver FT, Oudega M, Hagg T: Neurotrophins reduces degeneration of injured ascending sensory and corticospinal motor axons in adult rat spinal cord. *Exp Neurol* 2002; 175:282-96
12. Jorgen Rjen Boivie, Per Hansson and Uls Lindblom: Touch, Temperature, and Pain in Health and Disease: Mechanism and Assessment. IASP press Vol 3 1994; 295-338
13. Basbaum A, I, Gautron, M., Jazat F, Mayes M, and Gilbaud: The spectrum of fiber loss in a model of neuropathic pain in the rat: an electron microscopic study. *Pain* 1991; 47: 359-367
14. Lazorthes Y, Sagen J, Sallerin B, Tkaczuk J, Duplan H, Sol J,C, Tafani M, Bes J, C: Human chromaffin cell graft into the CSF for cancer pain management: a prospective phase II clinical study. *pain* 2000; 87: 19-32
15. Sagen J, Chromaffin cell transplants in the CNS: Basic and clinical update, In: R,P, Lanza and W,L, Chick: Year book of cell and tissue transplantation, Kluwer Academic Dordrecht 1997; 71-89
16. Eaton MJ, Herman JP, Jullien N, Lopez TL, Martinez M, Huang J: Immortalized chromaffin cell disimmortalized with Cre/Lox site-directed recombination for use in cell therapy for pain after partial nerve injury. *Exp Neurol* 2002; 175 (1):49-60
17. Flamig G, Engele J, Geerling T, Pezeshki G, Adler G, Reinshagen M: Neurotrophin and GDNF expression increases in rat adrenal glands during experimental colitis. *Neuroendocrinology lett* 2001; 22: 461-6
18. Harper G, P, Pearce, F, L, Vernon, C,A, Production of nerve growth factor by the mouse adrenal medulla. *Nature* 1976; 261: 251-253
19. Farinas I, Cano-Jaimez. M, Bellmut E, Soriano M: Regulation of neurogenesis by neurotrophins in developing spinal sensory ganglia. *Brain Res.* 2002; 57: 809-816
20. Zhang JY, Luo XG, Xian CJ, Liu ZH, Zhou XF: Endogenous BDNF is required for myelination and regeneration of injured sciatic nerve in rodents. *Eur J Neurosci* 2000; 124: 171-80
21. Heine W, Conant K, Griffin Jw, Hoke A: Transplant neural stem cell promote axonal regeneration through chronically denervated peripheral nerves. *Exp Neurol* 2004; 189 (2):231-40
22. Murray L, Kim D, Liu Y, Tobias C, Tessler A, Fischer I: Transplantation of genetically modified cells contributes to repair and recovery from spinal injury. *Brain Res Rev* 2002; 40: 292-300
23. Novikova Ln, Novikov Ln, Kellerth JO: Differential effects of neurotrophins on neuronal survival and axonal regeneration after spinal cord injury in adult rats. *J Comp Neurol* 2002; 452: 255-63
24. Zhou L., Baumgartner BJ, Hill-Felberg SJ, McGowen LR, Shine HD: Neurotrophins-3 expressed in situ induces axonal plasticity in the adult injured spinal cord. *J Neurosci* 2003; 23: 1424-31
25. Bregman BS, Coumans JV, Dai HN, Kuhn PL, Lynskey J, McAtee M, Sandhu F: Transplantation and neurotrophic factors increase regeneration and recovery of function after spinal cord injury. *Prog Brain Res* 2002; 137: 257-73
26. Graham, M, Ritchie J, and Henry J L: Nerve constriction in the ratL: model of neuropathic, surgical and central pain. *Pain* 1999; 83: 37-46

