

# Ultrastructural Study of Neuronal Death in Rat Hippocampus after Transient and Permanent Focal Cerebral Ischemia

Majid Asadi-Shekaari, Ph.D.<sup>1\*</sup>, Marzieh Panahi, Ph.D.<sup>2</sup>, Seyed Hassan Eftekhari Vaghefi, Ph.D.<sup>3</sup>, Ali Aboli Dokht Noughi Zadeh, M.Sc.<sup>3</sup>

1. Electron Microscopy Department, Kerman Neuroscience Research Center (KNRC), Kerman, Iran

2. Histology and Embryology Department, Medical school, Ahwaz Jondi-Shapour Medical University, Ahwaz, Iran

3. Anatomy Department, Medical School, Kerman Medical University, Kerman, Iran

\* Corresponding Address: P.O.Box: 76135-113, Electron Microscopy Department, Kerman Neuroscience Research Center (KNRC), Kerman, Iran  
Email: [m\\_asady@yahoo.com](mailto:m_asady@yahoo.com)

## Abstract

Received: 21/Sep/2008, Accepted: 13/Nov/2008

**Objective:** Morphological changes of CA1 neurons in rat hippocampus after transient and permanent focal cerebral ischemia were studied to clarify the nature of post-ischemic cell death in the subfield.

**Materials and Methods:** Male adult rats were divided into 3 groups: Control (Sham-operated), transient ischemic group (30 minutes of MCAO followed by 48 hours of reperfusion), and permanent ischemic group (48 hours of MCAO). After the mentioned times, deep anesthesia was induced in the rats and their brains were removed and processed for transmission electron microscopy (TEM) and evaluation.

**Results:** Electron-microscopic examination on day 2 showed key morphological signs of apoptosis in the permanent ischemic group, while morphological signs of necrosis were observed in the transient ischemic group.

**Conclusion:** These results suggest necrosis (as dominant mechanism of neuronal death after transient ischemia) and apoptosis (after permanent ischemia) to be involved in neuronal death.

**Keywords:** Cell Death, Rat, Hippocampus, Ischemia

Yakhteh Medical Journal, Vol 11, No 1, Spring 2009, Pages: 23-28

## Introduction

Apoptosis and necrosis are morphologically and biochemically distinguishable forms of cell death (1). Apoptosis is characterized by cell shrinkage, plasma membrane blebbing, chromatin aggregation, and DNA condensation. In contrast, necrosis manifests as cell swelling, organellar damage, disruption of membrane integrity, and cell lysis. Biochemical features of apoptosis include maintenance of ATP levels (2), activation of one or more cysteine proteases in the caspase family (3), and a loss of plasma membrane phospholipid symmetry (4). Necrosis is accompanied by rapid ATP depletion and dramatic changes in mitochondrial ultrastructure (5). The mode of cell death is of particular importance because necrotic cell death results in an inflammatory response involving activation of macrophage/microglia, whereas apoptosis does not elicit such a response (6). The sub-cellular events leading to cell death are fundamental to understanding an array of human disorders including cancer (7) and Stroke (8).

More than 90% of CA1 neurons die 1 week after forebrain ischemia (9, 10). The pathogenesis of this selective neuronal death is not fully understood and is under active investigation. Electron microscopy of hippocampus reveals morphological evidence of necrosis (11). Based on the results of several experiments, Nitatori et al. (12) conclude that delayed cell death of CA1 neurons in gerbil after brief global ischemia is not necrotic but apoptotic. However, efforts to label cerebral ischemia induced cell death as necrotic or apoptotic have generated controversy (13).

In the present study, ultrastructural changes of CA1 neurons in the rat hippocampus after transient and permanent focal cerebral ischemia due to middle cerebral artery occlusion (MCAO) were studied to clarify the nature of post-ischemic cell death in the subfields.

## Materials and Methods

Male adult NMRI rats (250-350) were used in the

study. Experimental procedures were approved by the ethics committee of Ahwaz Jondi-Shapour Medical University, Ahwaz, Iran. Before undergoing the experimental procedures, the animals were clinically normal, free of obvious infection or inflammation, and presented no neurological disorders. The animals were divided into 3 different groups: Sham-operated group, transient ischemic group (30 minutes of MCAO followed by 48 hours of reperfusion) and permanent ischemic group (48 hours of MCAO).

Due to the high mortality rate of animals in the experimental groups, each group consisted of at least three animals.

**Transient focal cerebral ischemia**

The animals were subjected to transient focal cerebral ischemia using the MCAO method (14). In brief, they were anesthetized with chloral hydrate (Sigma) (400 mg/kg). Under the operating microscope, the right common carotid artery (CCA) of each animal was incised at midline. After blocking all branches of the external carotid artery (ECA) and extra cranial branches of the internal carotid artery (ICA), a 4-0 nylon intraluminal suture was introduced into the cervical ICA and advanced intracranially to block blood flow into the MCA. After 30 minutes, the intraluminal suture was withdrawn and blood flow resumed. Rectal temperature was monitored continuously and maintained between 37±0.5 °C throughout anesthesia. After full recovery, neurological evaluation (15) was performed to ensure MCAO occurred, and animals without clinical signs were then excluded from the experiment.

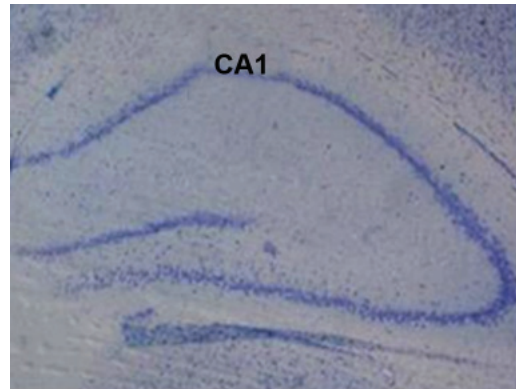
**Permanent focal cerebral ischemia**

Under chloral hydrate anesthesia, the left MCA was exposed using the Tamura et al. method (16). The ipsilateral CCA was then exposed. Ischemia resulted when ligation of the CCA immediately followed cautery of the MCA, which was coagulated from its junction with the olfactory tract to the inferior cerebral vein. The arterial occlusions were maintained until decapitation 48 hours later. Rectal temperature was monitored continuously and maintained between 37±0.5°C throughout anesthesia. After full recovery,

neurological evaluation (15) was performed to verify the occurrence of MCAO, and animals without clinical signs were excluded.

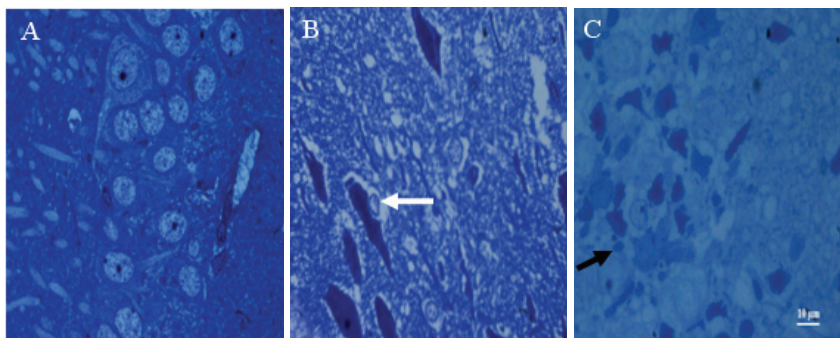
**Electron Microscopy Preparation**

After the prescribed survival time, the rats were re-anesthetized with chloral hydrate (400mg/kg), and were through the left ventricle transcardially perfused with 250 ml of heparinized saline solution followed by 100 ml of fixative solution compounded by 4% paraformaldehyde in a 0.1M phosphate buffer solution (PBS), with a PH of 7.4 and at room temperature. The brains were removed and immersed in the same fixative solution overnight. A 400-µm block of area CA1 (Fig 1) was dissected and fixed in buffered 2.5% glutaraldehyde (Merck) for an additional 48 hours. The sections were then washed in PB solution and postfixed in 1% OSO<sub>4</sub> for 2 hours at room temperature. After dehydration in ascending ethanol, they were embedded in Epon812 resin (TAAB, UK) and polymerized for 48 hours at 55°C.



**Fig 1: Photomicrograph of a coronal section of the hippocampus of a male rat stained with Thionin. The box indicates the analyzed area in this study.**

Semithin sections (0.3 µm) were stained with toluidine blue to identify CA1 regions (Fig 2). Subsequently, 70 nm sections were cut and stained with uranyl acetate and lead stain. Sections were examined with a Philips EM300 electron microscope.



**Fig 2: Light micrographs of semithin sections of CA1 hippocampal subfield of male rats stained by toluidine blue on day 2 after ischemia in the different groups. (A) sham-operated group, (B) transient ischemic group and (C) permanent ischemic group. (A) Micrograph showing a layer of pyramidal neurons with large and prominent nuclei. (B) Micrograph showing dark neurons. Inflammatory cell infiltration (White arrow). (C) Micrograph showing apoptotic neurons. Apoptotic body is considerable (Black arrow). Magnification: ×400**

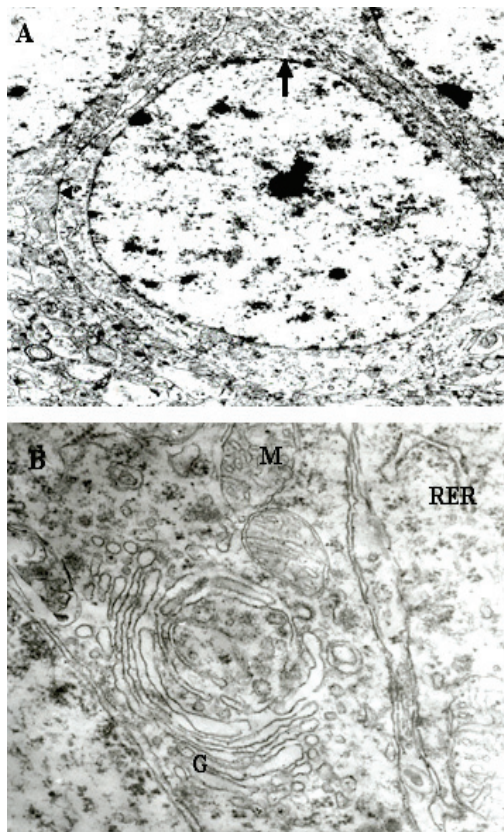
At least three specimens per animal were prepared, and for each specimen of sham-operated and experimental groups six grids were prepared of which three were studied.

## Results

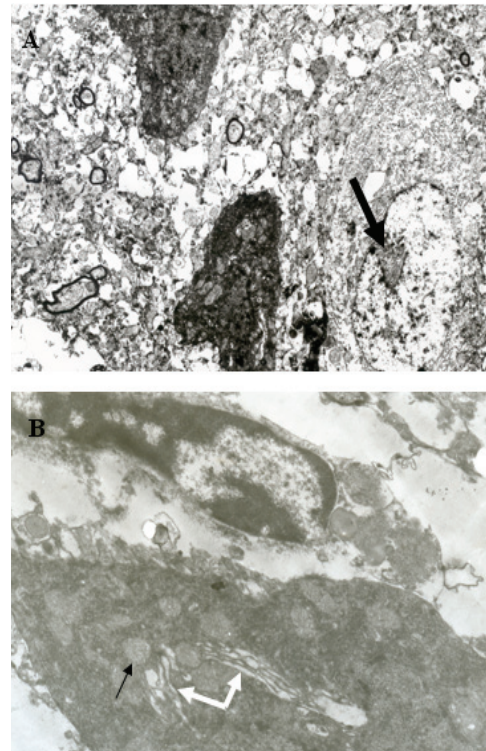
Light and electron microscopy observations in the study showed morphological changes in the CA1 subfield after 48 hours of ischemia.

### Light microscopy findings

In sham-operated animals, semithin sections of CA1 subfield showed a layer of cell bodies of pyramidal neurons with large and prominent nuclei (Fig 2A). At 48 hours after transient ischemia, the pyramidal neurons exhibited necrotic changes characterized by dark neurons with pyknotic nuclei and inflammatory cell infiltration (Fig 2B). At 48 hours after permanent ischemia, the neurons showed apoptotic changes characterized by formation of apoptotic bodies and loss of inflammatory cells (Fig 2C).



**Fig 3:** Electron micrograph of a typical CA1 pyramidal neuron from sham-operated rat group(A). (A) Intact cytoplasm within the somata and normal cell membrane (arrowhead). Nuclear membrane (black arrow) is smooth and the chromatin material is dispersed throughout the nucleus. (B) Electron micrograph with higher magnification shows rough endoplasmic reticulum (RER), Golgi apparatus (G) and mitochondria (M). Magnification in (A):  $\times 5200$ , in (B):  $\times 39000$



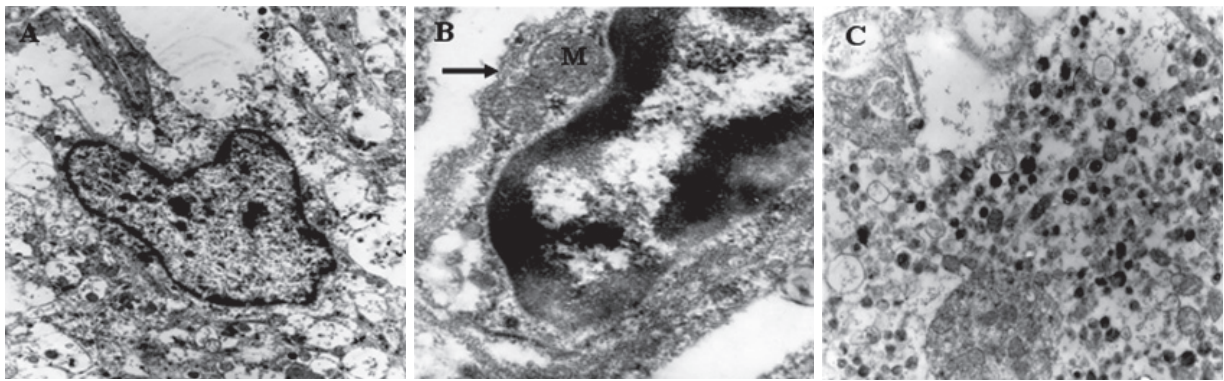
**Fig 4:** Electron micrograph of the ultrastructure of the CA1 pyramidal neurons on day 2 after 30 minutes of MCAO (transient ischemic group). (A) Pyramidal neurons showing different stages of degeneration. Note cytoplasmic alterations such as darkening of cytoplasm and swollen organelles. Nuclear lysis and nuclear membrane invagination (black arrow) are also noticeable. (B) Micrograph of higher magnification showing nuclear lysis, swollen golgi apparatus (G) and (RER) (white arrows) and mitochondria (M). Magnification in (A):  $\times 6195$ , in (B):  $\times 44100$

### Electron microscopy findings

In sham-operated animals, CA1 pyramidal cells had oval nuclei with evenly dispersed chromatin and clear nucleoli. Cytoplasmic membrane and nucleolemma were intact. The cytoplasm contained mitochondria of various sizes, well developed rough endoplasmic reticulum (RER) and characteristic polyribosomal rosettes (Fig 3A, B).

Two days after undergoing 30 minutes of MCAO, ultrastructure changes were observed in the CA1 neurons. In some cells, the changes were visible within the cytoplasm and nucleus as shown in (Fig 4 A, B). In this example, there were cytoplasmic darkening, mitochondrial swelling, nucleolemma invaginations indicating the shrinkage of the nuclei and/or nuclear lysis, swelling of the golgi apparatus and RER. The discontinuity of plasma membrane and nucleolemma was observed in some swollen cells.

Two days after permanent MCAO, ultrastructure observations showed chromatin aggregation and formation of apoptotic bodies. Plasma membrane and nucleolemma discontinuity were not observed in the swollen cells (Fig 5A, B, C).



**Fig 5: Electron micrograph of the ultrastructure of CA1 pyramidal neurons on day 2 after permanent ischemia. (permanent ischemic group). (A) Pyramidal neuron showing degenerative changes. Note nuclear deformity and chromatin aggregation. (B) Micrograph of higher magnification showing chromatin aggregation. Plasma membrane (arrow) and mitochondria (M) are intact. (C) Micrograph showing typical apoptotic bodies. Magnifications: (A):  $\times 6195$ , (B):  $\times 39000$  (C):  $\times 6195$**

## Discussion

The main result of this study is that the pyramidal CA1 neurons undergoing transient ischemia versus those undergoing permanent ischemia exhibit significantly different patterns of damage. In the CA1 subfield of rat hippocampus, the majority of neurons, starting from 48 hours after reperfusion, showed characteristic features of necrotic changes whereas neurons undergoing permanent ischemia exhibited key features of apoptotic changes.

The present study has shown the ischemic necrotic cell changes of CA1 pyramidal neurons in rat hippocampus following transient MCAO. In the CA1 subfield under a light microscope, we observed necrotic changes characterized by dark neurons with pyknotic nuclei and inflammatory cell infiltration. Under an electron microscope, we observed characteristic features of ischemic necrotic cell changes such as darkening of the cytoplasm, mitochondrial swelling, nucleolemma invagination and/or nuclear lysis, and swelling of Golgi apparatus and RER. Ischemic cell changes reported by Speilmayer (17), Schwartz-bloom et al. (18) and Winkelmann et al. (19) are similar to our findings.

Our light-microscopy evaluations showed the apoptotic changes of pyramidal CA1 hippocampal neurons following permanent MCAO. These changes included formation of apoptotic bodies and loss of inflammatory cells. Electron-microscopy observations showed chromatin aggregation and formation of apoptotic bodies, as well as undisrupted plasma and mitochondrial membranes. These results are in agreement with other studies (20, 21).

Recent studies with molecular biological approaches, have shown DNA fragmentation in the CA1 region after ischemia suggesting that apoptosis is involved in the neuronal damage (22). Other recent studies however, suggest the existence of a range of intermediate morphological processes which includes simultaneous apoptotic and necrotic features (13).

More interestingly, another morphological change in

neurons of mouse hippocampus following transient hypoxic-ischemia is explained by Fukuda et al. (23). Based on their report, perikarya of degenerating neurons shrank as in apoptosis, but apoptotic bodies were not observed and organelles other than mitochondria disappeared almost completely from the perikarya. Furthermore, neither plasma nor mitochondrial membranes were disrupted further indicating that these changes differed from those in typical necrosis.

The above discrepancies may be due to one or a combination of the use of non-specific detection methods (e.g., TUNEL) for DNA fragmentation, different time-points at which neurons are examined following the ischemic insult, as well as conflicting biochemical and morphologic findings (20).

A variety of stimuli can induce apoptosis, including oxidative insults (24), trophic factor withdrawal (25) and metabolic compromises (26). In some cases such as exposure to excitatory amino acids and oxidative insults, whether cells die by apoptosis or by necrosis depends upon insult intensity (27). For example, exposure of cultured PC12 cells or hippocampal neurons to low concentrations of 4-hydroxynoneal (HNE), a toxic product of membrane lipid peroxidation, induces apoptosis, whereas higher HNE concentrations induce necrosis (28). It has been suggested that ischemia may trigger either necrosis or apoptosis depending on insult severity, the intracellular free  $Ca^{2+}$  levels, and availability of growth factor (20).

There is escalating evidence that mitochondria play a key role in both necrotic and apoptotic neuronal death after acute cerebral ischemia (29). According to Solenski's study (30), neuronal mitochondria undergoing transient versus permanent ischemia exhibit significantly different patterns of injury. Structural damage to neuronal mitochondria of neocortex occurs more acutely and to a greater extent during the reperfusion phase in comparison to during the ischemic phase. One explanation is based on the well-established fact that during reoxygenation, the perfused neuron is ex-

posed to potential toxins including oxygen free radicals and important proinflammatory mediators (31). Furthermore, there is increasing in-vivo evidence that oxidative stress associated with reoxygenation generates free radicals, which are believed to be injurious or even lethal to mitochondria (32). There remains a vigorous debate over the role of mitochondrial membrane rupture and the release of proapoptotic factors including cytochrome c in initiating apoptotic cell death (33).

However, severe damage to mitochondria that occurs during the reperfusion phase may lead to necrosis, while mild damage to mitochondria due to permanent ischemia may lead to apoptosis. This fact (different mitochondrial injuries) may explain the observed different death patterns of CA1 neurons in different conditions.

## Conclusion

In summary, these results suggest necrosis as the dominant mechanism of neuronal death after transient ischemia, and apoptosis as the dominant mechanism of neuronal death after permanent ischemia. However, it must be also be noted that multiple techniques at different time points after ischemia are essential to ascertain the type of death in the CA1 neurons. More investigations are required in this respect in order to understand the biochemical and molecular pathways involved in producing neuron loss following brain ischemia.

## Acknowledgments

This study was supported by a grant from Ahwaz Medical University. The authors are grateful for the sincere help from Mrs. Mahdavi Nia and Miss. Minoo Mahmoudi, our colleagues at the Journal of Kerman University of Medical Sciences. The authors declare no conflict of interests.

## References

1. Steller H. Mechanisms and genes of cellular suicide. *Science*. 1995; 267: 1445-1449.
2. Kroemer, G, Zamzami N, Susin SA. Mitochondrial control of apoptosis. *Immunol Today*. 1997; 18: 44-51.
3. Miller DK. The role of caspase family of cystein proteases in apoptosis. *Semin Immunol*. 1997; 9: 35-49.
4. Savill J. Recognition and phagocytosis of cells undergoing apoptosis. *Br Med Bull*. 1997; 53: 491-508.
5. Mattson MP, Zhang Y, Bose S. Growth factors prevent mitochondrial dysfunction, loss of calcium homeostasis, and cell injury, but not ATP depletion in hippocampal neurons deprived of glucose. *Exp Neurol*. 1993; 121: 1-13.
6. Kruman I, Bruce-Keller AJ, Bredsen DE, Waeg G, Mattson MP. Evidence that 4-hydroxyneal mediates oxidative stress-induced neuronal apoptosis. *J Neurosci*. 1997; 5089-5100.
7. Harmon BV, Allan DJ. Apoptosis. *Adv Genet*. 1997; 35: 35-56.
8. Chalmers-Redman RM, Fraser AD, Ju WY, Waida J, Tatton NA, Tatton WG. Mechanisms of nerve cell death: apoptosis or necrosis after cerebral ischemia. *Int Rev*

*Neurobiol*. 1997; 40: 1-25.

9. Petitto CK, Feldmann E, Pulsinelli WA, Plum F. Delayed hippocampal damage in humans following cardiorespiratory arrest. *Neurology*. 1987; 37: 1281-1286.
10. Farazifard R, Ezat Abadi M, Malekpour R, Eftekhari SH, Aboli Nooghy Zadeh A, Sheibani V. Effect of Aspirin on morphology of CA1 hippocampal neurons following ischemia induction in male rat. *Yakhteh*. 2005, 7(1): 29-34.
11. Colbourne F, Sutherland GR, Auer AN. Electron microscopy evidence against apoptosis as the mechanism of neuronal death in global ischemia. *J Neurosci*. 1999; 19: 4200-4210.
12. Nitatori T, Sato N, Waguri S, Karasawa Y, Araki H, Shibani K, et al. Delayed neuronal death in the CA1 pyramidal cell layer of the gerbil hippocampus following transient ischemia is apoptosis. *J Neurosci*. 1995; 15: 1001-1011.
13. Zeng YS, Xu ZC. Co-existence of necrosis and apoptosis in rat hippocampus following transient forebrain ischemia. *Neurosci Res*. 2000; 37: 113-125.
14. Longa EZ, Weinstein PR, Carlson S, Cummins SR. Reversible middle cerebral artery occlusion without craniectomy in rats. *Stroke*. 1989; 20: 84-91.
15. Garcia JH, Wagner S, Liu KF, Hu XJ. Neurological deficit and extent of neuronal necrosis attributable to middle cerebral artery occlusion in rats. *Stroke*. 1995; 26: 627-635.
16. Tamura A, Graham DI, McCulloch J, Teasdale GM. Focal cerebral ischemia in the rat: 1. Description of technique and early neuropathological consequences following middle cerebral artery. *J Cereb Blood Flow Metab*. 1981; 1: 53-60.
17. Spielmeyer W. Zür pathogenese orlich elektiven gehirneränderungen, Z. Ges. Neurol. Psychiatr, 1925; 99: 756-776, quoted by Lipton P. Ischemic cell death in brain neurons. *Physiol Rev*, 1999; 79: 1431-1568.
18. Schwartz-Bloom RD, Miller AD, Evenson DA, Crain BJ, Nadler JV. Benzodiazepines protect hippocampal neurons from degeneration after transient cerebral ischemia: an ultrastructural study. *Neurosci*. 2000; 98(3): 471-484.
19. Winkelmann ER, Charcansky A, Faccioni-Heuser MC, Netto CA, Achaval M. An ultrastructural analysis of cellular death in the CA1 field in the rat hippocampus after transient forebrain ischemia followed by 2, 4 and 10 days of reperfusion. *Anat Embryol (Berl)*. 2006; 211(5): 423-434.
20. Choi DW. Ischemia-induced neuronal apoptosis. *Curr Opin Neurobiol*. 1996; 6: 667-672.
21. Charriaut-Marlangue C, Aggoun-Zouaoui D, Represa A, Ben-Ari Y. Apoptotic features of selective neuronal death in ischemia, epilepsy and gp 120 toxicity. *TINS*. 1996; 19: 109-114.
22. MacManus JP, Linnik MD. Gene expression induced by cerebral ischemia: an apoptotic perspective. *J Cereb Blood Flow Metab*. 1997; 17: 825-832.
23. Fukuda T, Wang H, Nakanishi H, Yamamoto K, Kosaka T. Novel non-apoptotic morphological changes in neurons of the mouse hippocampus following transient hypoxic-ischemia. *Neurosci Res*. 1999; 33(1): 49-55.
24. Bredesen DE. Neural apoptosis. *Ann Neurol*. 1995; 38: 839-851.
25. Oppenheim RW. Cell death during development of the nervous system. *Annu Rev Neurosci*. 1991; 14: 435-501.
26. Marton A, Mihalik R, Bratincsa A, Adelef, V, Petak I, Vegh M, et al. Apoptotic cell death induced by inhibitors of energy conservation-Bcl-2 inhibits apoptosis down-stream of a fall of ATP level. *Eur J Biochem*. 1997; 250: 467-475.

## Ultrastructural Study of Neuronal Death

27. Pang Z, Geddes JW. Mechanisms of cell death induced by the mitochondrial toxin 3-nitropropionic acid: acute excitotoxic necrosis and delayed apoptosis. *J Neurosci.* 1997; 17: 3064-3073.
28. Kruman I, Bruce-Keller AJ, Bredesen DE, Waeg G, Mattson MP. Evidence that 4-hydroxynoneal mediates oxidative stress-induced neuronal apoptosis. *J Neurosci.* 1997; 17: 5089-5100.
29. Nicholls Dg, Budd SL. Mitochondria and neuronal survival. *Physiol Rev.* 80: 315-360.
30. Solenski NJ, diPierro CG, Trimmer PA, Kwan AL, Helms GA. Ultrastructural changes of neuronal mitochondria after transient and permanent cerebral ischemia. *Stroke.* 2002; 33: 816-824.
31. Ritter LS, Orozco JA, Coull BM, McDonagh PF, Rosenblum WI. Pro-oxidants and mitochondrial calcium: their relationship to apoptosis and oncogenesis. *FEBS Lett.* 1993; 335: 104-107.
32. Pintadosi CA, Zhang J. Mitochondrial generation of reactive oxygen species after brain ischemia in the rat. *Stroke.* 1996; 17: 327-331.
33. Dirnagl U, Ladecola C, Moskowitz MA. Pathobiology of ischaemic stroke: an integrated review. *Trends Neurosci.* 1999; 22: 391-397.
-